



# Prevena Restor™

Postoperative Recovery

## Use of 3M™ Prevena Restor™ Bella•Form™ Incision Management System in bilateral, nipple-sparing mastectomy

Regina M. Fearmonti, MD; Alon Aesthetics/Fearmonti Plastic Surgery, San Antonio, Texas

### Patient

A 42-year-old female presented to the surgical clinic after a prior diagnosis of invasive ductal carcinoma of the right breast (**Figure 1**). The patient presented with no concomitant comorbidities. Her medical history included asthma for which she had no recent use of her rescue inhaler or hospitalisation.

### Procedure

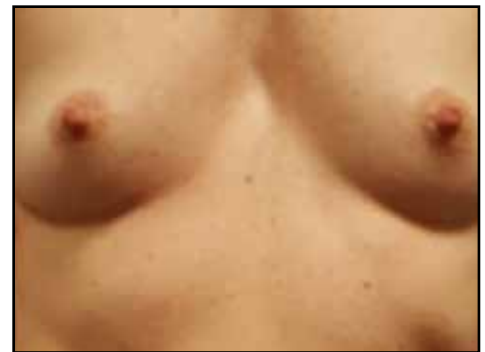The patient underwent bilateral, nipple-areolar-sparing mastectomy. The mastectomy produced two incisions at the inframammary folds (**Figure 2A**). Bilateral pre-pectoral direct-to-implant reconstruction was performed with round silicone implants (Natrelle Inspira® SSX 340cc BI, model SSX-340; Allergan, plc, Dublin, Ireland). The implants were covered with an acellular dermal matrix. Bilateral drains were inserted and positioned laterally. Closure of the surgical incisions was achieved via subcuticular suturing (**Figure 2B**).

### Initial treatment/application of 3M™ Prevena Restor™ Bella•Form™ Incision Management System

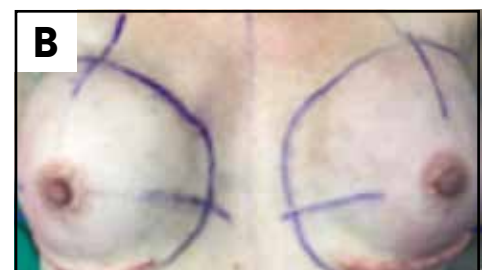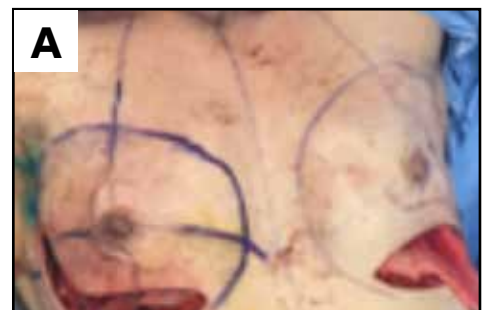Prevena Restor™ Bella•Form™ Incision Management System was enlisted to help reduce tensile force across the closed incisions, manage the incision and surrounding area, and to help hold the edges of the closed incisions together. The 3M™ Prevena Restor™ Bella•Form™ Dressing (21cm x 19cm) was placed along the inframammary fold and mastectomy flap incisions (**Figure 3A**). The Prevena Restor™ Bella•Form™ Dressing was positioned so as the drains exited outside of the perimeter of the dressing (**Figure 3B**). The 3M™ Prevena Restor™ Therapy unit applied -125mmHg of subatmospheric pressure for 6 days (**Figure 3C**).

### Discharge and follow-up

On postoperative day (POD) 6, the patient returned to the clinic for a follow-up visit (**Figure 4A**). The Prevena Restor™ Bella•Form™ Incision Management System was removed to evaluate the reconstructed breasts, tissue integrity, and the incisions (**Figure 4B**). Upon dressing removal, some skin wrinkling was noted, which was temporary and did not cause any skin breakdown. Following the evaluation, the Prevena Restor™ Bella•Form™ Incision Management System was reapplied to manage the incision, reduce tensile force across the closed incision and to help hold the edges of the closed incision together. On POD 7, the patient returned to the clinic and the dressing was removed due to loss of seal as the patient was diaphoretic during the evening. Although erythema was present, this was not caused by the dressing (**Figure 5**). The patient was transitioned to a cotton brassiere with no pressure as well as prescribed topical silver sulfadiazine (Silvadene® Cream, Pfizer Inc., New York, NY) and oral ciprofloxacin. The drains were removed after 10 days. At POD 65, the incisions were completely healed, and both nipples were viable (**Figure 6**).



**Figure 1.** Patient at presentation after diagnosis of invasive ductal carcinoma of the right breast.



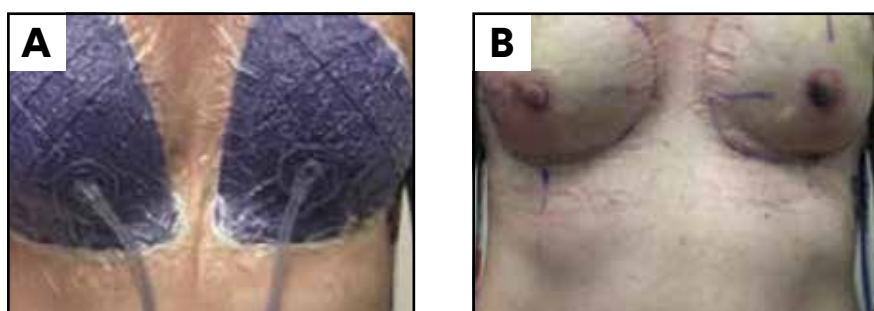
**Figure 2.** Bilateral, nipple-areolar-sparing mastectomy. **A.** Two surgical incisions at the inframammary folds resultant of bilateral mastectomy. **B.** Closure of bilateral incisions via subcuticular suturing.

## User experience

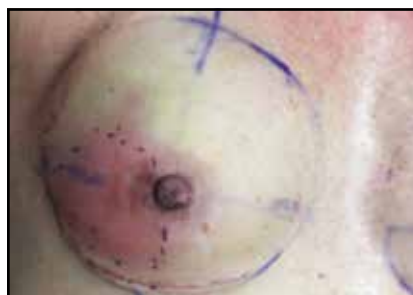In this case, the 3M™ Prevena Restor™ Bella•Form™ Incision Management System managed the incisions, helped hold the edges of the incision together, bolstered the mastectomy flap, and helped reduce skin oedema. Nipple viability was maintained.



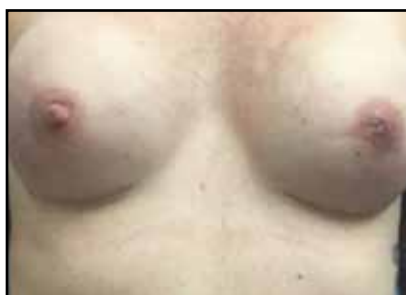**Figure 3.** Application of 3M™ Prevena Restor™ Bella•Form™ Incision Management System. **A.** Placement of 3M™ Prevena Restor™ Bella•Form™ Dressing (21cm x 19cm) along the inframammary fold and mastectomy flap incisions. **B.** Dressing placement did not obstruct drains. **C.** The initiation of 3M™ Prevena Restor™ Therapy (-125mmHg) to the closed incisions.



**Figure 4.** POD 6 postoperative follow-up visit. Prevena Restor™ Bella•Form™ Incision Management System was reapplied. **A.** Patient before the removal of Prevena Restor™ Bella•Form™ Dressing. **B.** Reconstructed breasts after removal of Prevena Restor™ Bella•Form™ Dressing and before the reapplication of Prevena Restor™ Bella•Form™ Incision Management System.



**Figure 5.** On POD 7, erythema was noted bilaterally on the reconstructed breasts after removal of Prevena Restor™ Bella•Form™ Dressing.



**Figure 6.** POD 65, incisions were completely healed, and both nipples were viable.

Photos and patient information courtesy of Dr. Regina M. Fearmonti, Alon Aesthetics/Fearmonti Plastic Surgery.

**Note:** As with any case study, the results and outcomes should not be interpreted as a guarantee or warranty of similar results. Individual results may vary depending on the patient's circumstances and condition.

**Note:** Specific indications, contraindications, warnings, precautions and safety information exist for these products and therapies. Please consult a clinician and product instructions for use prior to application. This material is intended for healthcare professionals.

# 3M

**3M United Kingdom PLC**  
Charnwood Campus  
10 Bakewell Road  
Loughborough  
LE11 5RB  
01509 611 611

**3M Ireland Ltd**  
The Iveagh Building  
The Park, Carrickmines  
Dublin  
D18 X015  
Ireland  
1 800 320 500

© 2021 3M. All rights reserved. 3M and the other marks shown are marks and/or registered marks. Unauthorised use prohibited.  
PRA-PM-EU-00331 (12/21)