

Temporary closure using Solventum™ AbThera™ Open Abdomen Negative Pressure Therapy following motor vehicle accident

Patient

A 37-year-old male pedestrian was struck by an automobile. At emergency room presentation, systolic blood pressure was 70mmHg and heart rate was 118 beats per minute.

Diagnosis

The abdominal FAST (Focused Assessment with Sonography for Trauma) was positive and an emergency laparotomy was performed. Findings included massive bleeding from a grade IV liver injury.

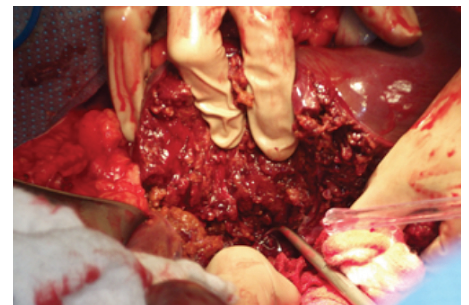
Management

Midline laparotomy and a right subcostal incision for exposure of the posterior liver were performed. Right lobe liver resection was also performed (A). During the operation, the patient remained hypotensive, the pH was 7.02, and temperature was 34.4°C. Massive transfusion protocol consisted of 22 units of packed red blood cells, 15 units of FFP and 3 units of platelets. Patient developed severe bowel edema (B). Treatment included closure of the right subcostal incision, damage control with perihepatic packing (9 perihepatic packs) and temporary closure of the laparotomy wound with Solventum™ AbThera™ Therapy. The Solventum™ AbThera™ Fenestrated Visceral Protective Layer (VPL) was tucked under the peritoneum to completely cover the viscera and protect abdominal contents (C). The Solventum™ AbThera™ Perforated Foam was cut into size and shape and was placed over the VPL (D). The Solventum™ V.A.C.® Drape and tubing were placed over the dressing to create a seal, and the tubing was connected to the negative pressure therapy unit at -125mmHg (E). The patient received standard ICU care, including mechanical ventilation and fluid resuscitation.

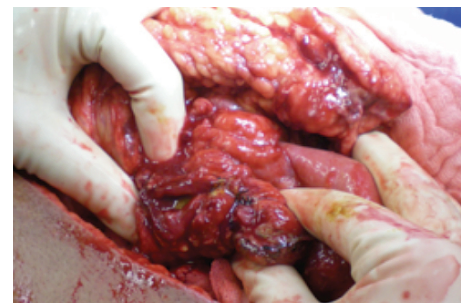Dressing changes were performed on Days 2, 4, and 7 with definitive closure on Day 9 (F). The post-operative recovery was uneventful.

Clinical outcomes

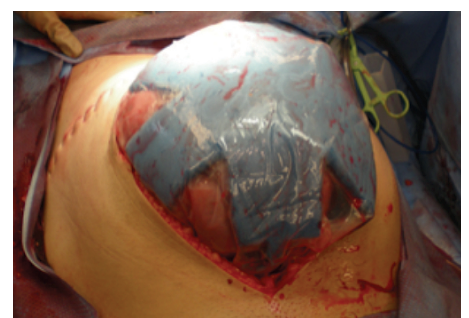
Optimal temporary abdominal wall closure was critical for successful definitive primary fascial closure in this case.



A. Right hepatic vein ligation and right lobe liver resection.



B. Damage control surgery for massive bowel edema.



C. Application of AbThera Fenestrated Visceral Protective Layer.

User experience

In this case, Solventum™ AbThera™ Open Abdomen Negative Pressure Therapy simplified a complex problem and allowed early definitive abdominal wall closure, thus helping to reduce the risks associated with the open abdomen.

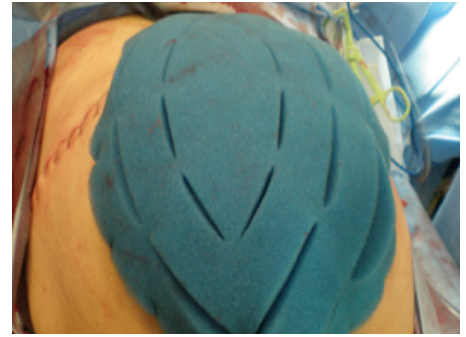Economic value

Early definitive closure for this patient prevented complications associated with the chronic open abdomen, such as the development of an incisional hernia, and need of a subsequent operation.

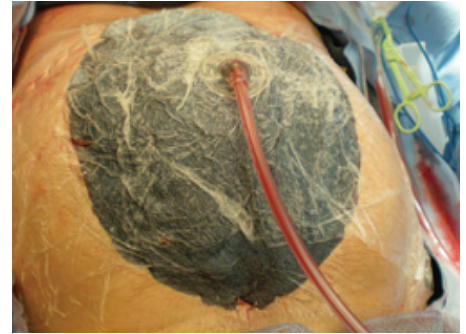Patient data and photos courtesy of Demetrios Demetriades, MD, PhD, FACS Professor of Surgery Director, Division of Acute Care Surgery, Los Angeles County and University of Southern California Medical Center, Los Angeles, CA.

As with any case study, the results and outcomes of this patient should not be interpreted as a guarantee or warranty of similar results. Individual results may vary depending on the patient's circumstances and condition.

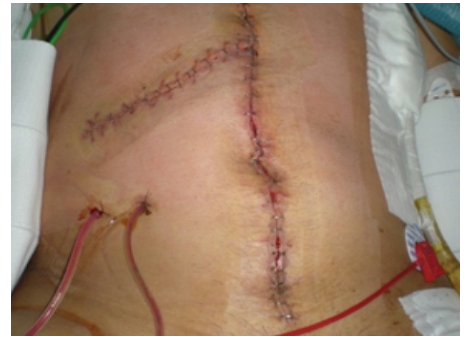Solventum™ AbThera™ SensaT.R.A.C.™ Open Abdomen Dressing and Solventum™ AbThera™ Advance Open Abdomen Dressing are designed for use with the negative pressure wound therapy provided by the Solventum™ V.A.C.® Ulta™ Therapy Unit. When using the V.A.C.® Ulta™ Therapy Unit, do not select the Solventum™ Veraflo™ Therapy option. See Instructions for Use.



D. The Solventum™ AbThera™ Perforated Foam was measured and cut to fit inside the exposed abdominal cavity.

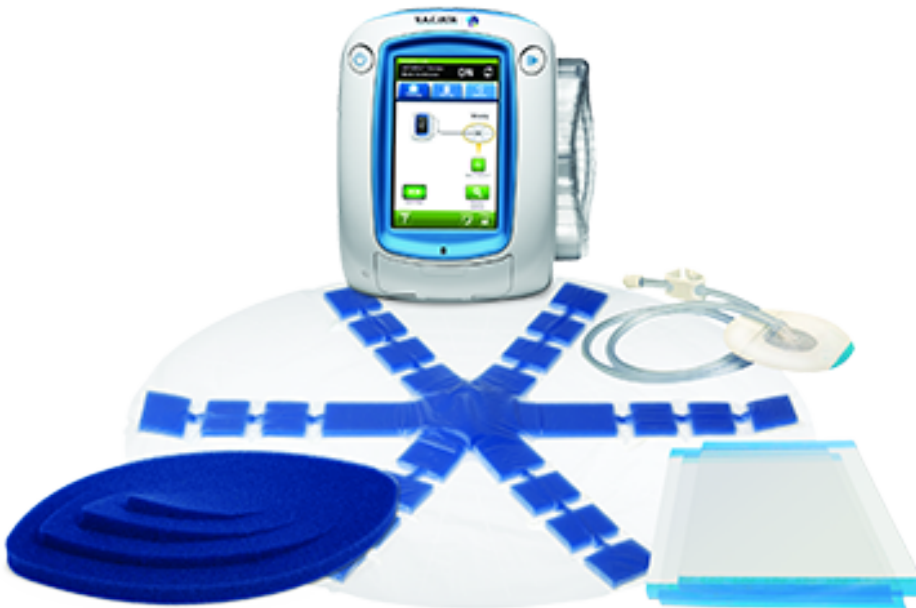

E. AbThera Therapy was used for 9 days.



F. Definitive closure on Day 9.

AbThera Therapy



Solventum Advanced Wound Care
12930 IH10 W
San Antonio, TX 78249
USA

Phone 800-275-4524
Web Solventum.com

Note: Specific indications, contraindications, warnings, precautions and safety information exist for these products and therapies. Please consult a clinician and product instructions for use prior to application. This material is intended for healthcare professionals. Rx only.

© Solventum 2025. Solventum, the S logo, AbThera and other trademarks are trademarks of Solventum or its affiliates. Other trademarks are the property of their respective owners.

70-2013-1032-6 PRA-PM-US-03160 (08/21)