

Solventum™ AbThera™ Open Abdomen Negative Pressure Therapy first mention

Use of Solventum™ AbThera™ Advance Open Abdomen Dressing in an abdominal pneumoperitoneum

Luis G. Fernández, MD, FACS, FASAS, FCCP, FCCM, FICS
Professor of Surgery, University of Texas Health Science Center, Tyler, TX;
University of Texas, Arlington, TX; Trinity Mother Frances Health System, Tyler, TX

Patient

A 69-year-old male presented to the emergency department with abdominal pain. Previous medical history included stage 4 lung cancer, stomach cancer, previous chemotherapy treatment. Previous surgical history included carotid stent placement, cervical spine surgery, coronary stent placement, and skin biopsy.

Initial treatment and application of AbThera Advance Dressing

The patient was seen at an outside facility and diagnosed with pneumoperitoneum on an abdominal computed tomography (CT) scan. Laboratory blood work indicated an elevated white blood cell count potentially due to early sepsis/septic shock. A CT scan indicated a large left pleural effusion (Figure 1) and pneumoperitoneum of the abdomen (Figure 2).

Operating room visit 1

An exploratory celiotomy, abdominal washout, appendectomy, and cholecystectomy was performed (Figure 3). Pleural fluid was collected and sent for cytology analysis. A biopsy of the perforated ulcer was obtained and was negative for malignancy. The Kocher Maneuver with modified Cellan-Jones patch of the perforated duodenal ulcer was performed. The abdomen was irrigated with 3 L of normal saline and 2 L of hypochlorous acid with a 10-minute dwell time. After removal of the irrigation solution, a fibrin sealant was added to the Cellan-Jones Patch.

AbThera Advance Dressing was applied to the open abdomen (Figure 4)

Following surgery, the patient was transferred to the surgical intensive care unit/shock trauma unit for recovery. During this stay, the patient was tachycardic, hypotensive, and had low central venous pressure despite receiving 4 L of

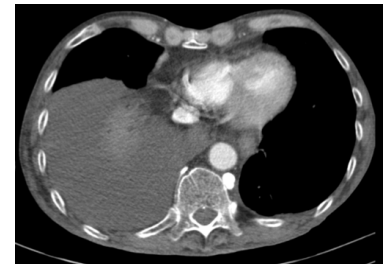

Figure 1. Chest CT scan showing large left pleural effusion (white arrow).

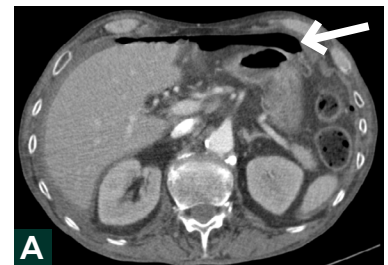

Figure 2. Abdominal CT scan showing pneumoperitoneum (white arrow).

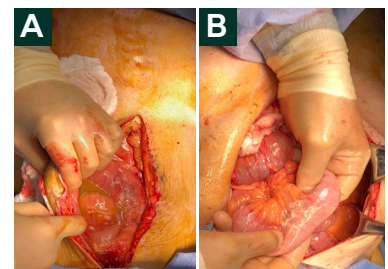


Figure 3. Exploratory celiotomy. A. 4 L of gastric succus; B. diffuse fibrin deposition.

intravenous fluids in the emergency room and intraoperatively. The patient was aggressively resuscitated with crystalloids and 25% albumin. Additionally, the patient received a continuous octreotide and proton pump inhibitor infusion, and 25% albumin. Additionally, the patient received a continuous octreotide and proton pump inhibitor infusion, broad spectrum antibiotics, and treatment for *Helicobacter pylori*. On post-operative day 3, an upper gastrointestinal series study was performed and indicated a small contained leak.

Operating room visit 2

The patient underwent a second open abdomen surgery to repair the contained duodenal leak.

An endoluminal closure of the 2 mm duodenal leak was attempted; however, this was unsuccessful. The patient underwent exploratory celiotomy, open repair of the duodenal leak with primary closure of the leak and mobilization of omentum using revised modified Cellan-Jones patch) with the addition of falciform ligament as a buttress. A RUQ-Paracolic 10 mm JP drain was placed followed by mesenteric shaving of suspected peritoneal metastases, placement of fibrin sealant on the duodenal repair, and placement of an adhesion barrier in the pelvis. A second Solventum™ AbThera™ Advance Open Abdomen Dressing was then applied (Figure 5).

Twenty-four hours after the duodenal leak repair, the leak remained closed and no fibrin deposition or abscess was noted.

Operating room visit 3

A third exploratory celiotomy was performed with abdominal washout, application of adhesion barrier, and abdominal closure. Bupivacaine liposome injectable suspension was added to the incision after closure of the fascia. Solventum™ Prevena™ Incision Management System was applied over the clean, closed incision and left in place for 7 days (Figure 6).

Discharge and follow-up

The patient was discharged to hospice after 12 days in the hospital. The patient had stable vitals without abdominal pain and was tolerating a general diet at discharge.

Patient data and photos courtesy of Dr. Luis Fernandez, University of Texas Health Science Center, Tyler, TX; University of Texas, Arlington, TX; Trinity Mother Frances Health System, Tyler, TX.

As with any case study, the results and outcomes of this patient should not be interpreted as a guarantee or warranty of similar results. Individual results may vary depending on the patient's circumstances and condition.

Solventum™ AbThera™ SensaT.R.A.C.™ Open Abdomen Dressing and AbThera Advance Dressing are designed for use with the negative pressure wound therapy provided by the Solventum™ V.A.C.® Ultra™ Therapy Unit. When using the V.A.C.® Ultra Therapy Unit, do not select the Solventum™ Veraflo™ Therapy option. See Instructions for Use.

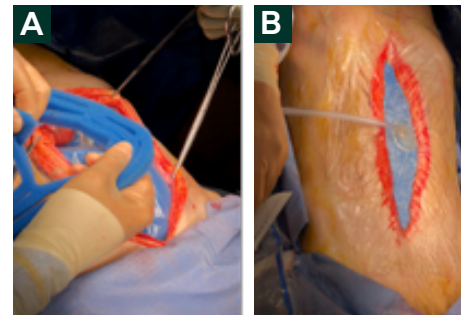


Figure 4. Placement of AbThera Advance Dressing. A. Placement of Solventum™ AbThera™ Fenestrated Visceral Protective Layer and sizing of Solventum™ AbThera™ Perforated Foam; B. Application of Solventum™ SensaT.R.A.C.™ Pad

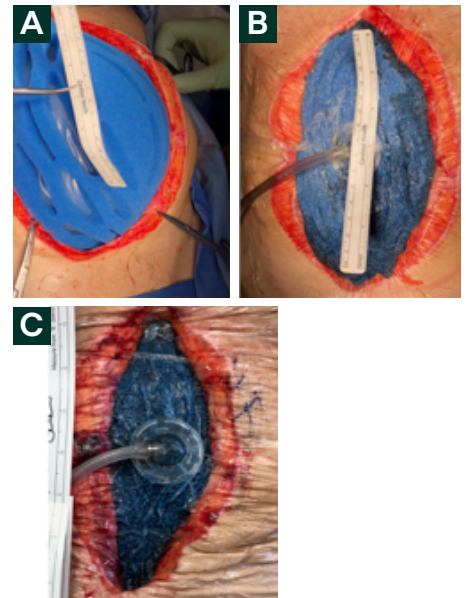


Figure 5. Application of second AbThera Advance Dressing. A. Application of AbThera Advance Perforated Foam (incision defect is 14 cm x 18 cm); B. Reduction of incision defect after negative pressure initiation (incision defect is 13 cm x 16.5 cm); C. Incision defect after 24 hours of AbThera Advance Dressing use (incision defect 10.16 cm x 16.5 cm)

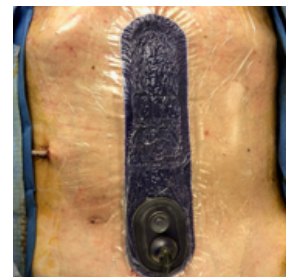

Figure 6. Application of Prevena Incision Management System. Dressing application



Solventum Advanced Wound Care
12930 IH10 W
San Antonio, TX 78249
USA

Phone 800-275-4524
Web Solventum.com

Note: Specific indications, contraindications, warnings, precautions and safety information exist for these products and therapies. Please consult a clinician and product instructions for use prior to application. This material is intended for healthcare professionals. Rx only.

©Solventum 2026. Solventum, the S logo, AbThera and other trademarks are trademarks of Solventum or its affiliates. Other trademarks are the property of their respective owners.

70-2013-1048-2 PRA-PM-US-03174 (05/21)